

Pilomatrixoma of the Cheek – A Case Report

Mohd Khairul Anwar Mohd Tahir^{1,3}, Anand Ramanathan^{*1,2}, George Boey Teik Foo⁴, Saravanan Gopalan³, Marzuki Bin Zainal Abidin³, Fairuz Abdul Rahman¹

KEYWORDS

Pilomatrixoma, Calcifying epithelioma of Malherbe, Benign calcifying epithelioma, Benign appendageal neoplasm, Hair follicle, Head and neck tumour

ABSTRACT

Pilomatrixoma is an uncommon benign tumour arising from the matrix and inner sheath of a normal hair follicle as well as hair cortex. It is usually presented as a superficial, solitary, firm mass which is asymptomatic and slowly growing. It accounts for about 0.2% of all routine skin specimens and may poses a diagnostic challenge as it may resemble other common benign lesions found in the head and neck region. We report a case of a 33-year old men presented to us with a pilomatrixoma of the right cheek, surgical management and histological findings.

INTRODUCTION

Pilomatrixoma is an uncommon benign tumour arising from the matrix of the hair follicle [1]. It was first reported in 1880 by Malherbe and Chenantis as a calcifying epithelioma, believing it to be a sebaceous gland tumour [2]. Since 1905, this uncommon neoplasia has been called calcifying epithelioma of Malherbe. Forbis & Helwig (1961) proposed the term pilomatrixoma which is more etymologically correct to avoid a connotation of malignancy [3]. Pilomatrixoma also known as pilomatricoma. It is a benign cutaneous adnexal neoplasm, originating from a normal hair follicle matrix and inner sheath cells as well as hair cortex, occurs in all age groups and representing 0.2% of all skin specimens [4]. Majority of pilomatrixoma cases arising in the head and neck region as well as upper

extremities, most of the cases found at the hair-bearing areas. Pilomatrixoma commonly presents as a solitary, slow growing painless, firm, subcutaneous or intradermal nodule of less than 3 cm in diameter. However, giant pilomatrixoma more than 5 cm in size have been reported. It is reported that pilomatrixomas have shown a female predominance with a female: male ratio of 3:2, and about 30-50% of cases found in young adult at the first two decades of life (60%) [5]. Caucasians are most affected [6]. They present as an asymptomatic, mobile and hard swelling which commonly occur in the head and neck region [6,7]. In rare occasions, patient may present with multiple pilomatrixomas, and it may be associated with other disease or syndromes such as myotonic dystrophy (autosomal dominant disorders) [8], Gardner syndrome [9], Turner's syndrome [10] and Rubinstein-Taybi syndrome [11]. This case report presents a case of pilomatrixoma of the cheek and discuss the clinical, radiographic, histopathologic characteristics and surgical management of these lesions along with relevant literature review.

CASE REPORT

A 33-year-old male presented to the Department of Oral and Maxillofacial Surgery, Queen Elizabeth Hospital, Kota Kinabalu, Sabah, Malaysia with right cheek swelling at the right parotid region anterior

¹Department Department of Oral & Maxillofacial Clinical Science, Faculty of Dentistry, University of Malaya, Kuala Lumpur, Malaysia.

²Oral Cancer Research & Coordination Centre, Faculty of Dentistry, University of Malaya, Kuala Lumpur, Malaysia.

³Dept of Oral Maxillofacial Surgery, QE Hospital, Kota Kinabalu, Sabah, Malaysia.

⁴Dept of Oral Medicine & Pathology, QE Hospital, Kota Kinabalu, Sabah, Malaysia.

*Correspondence: drnanand@um.edu.my

to the right-side angle of the mandible (Figure 1a). Patient unable to provide his exact age and claimed to have the swelling since childhood. The painless swelling has been gradually increasing in size and reached up to the present size of 3.0 cm x 3.0 cm. Swelling was not associated with any other symptoms. Patient has a history of pulmonary tuberculosis and had completed treatment. He also has history of epilepsy but currently well controlled with anti-epileptic medication. The last episode of epileptic attack was recorded about a year ago, which was short and lasted around 2-3 minutes and not associated with total loss of consciousness.

Extra-oral examination revealed a single, localized, swelling at the right facial region specifically located at the anterior part of angle of mandible. The swelling appeared ovoid with well-defined margin and is covered by skin with normal colour. This lesion was bony hard on palpation, non-tender and mobile. It was located between the skin and right masseter muscle. All the lymph nodes of the head and neck region were not palpable. There was another localized swelling of about 1.0 cm x 1.0 cm at the right temporal region with the same consistency as this lesion.

Intraoral examination revealed poor oral hygiene and multiple retained roots were noted. The extra-oral swelling on the right side of the face was not palpable intraorally. The Dental Panoramic Tomography (DPT) confirmed presence of multiple retained roots associated with 16, 21, 25, 27, 37, 36, 33, and 47. It also showed a well-defined radiopaque mass on the right side of the mandible, anterior to the angle of right side of mandible measuring about 3.0 cm x 3.0 cm in size (Figure 1b).

Computed Tomography (CT) scan of the right facial region showed a non-infiltrating well defined hyperdense lesion (Figure 1c and 1d) noted at the lateral part of the right mandible. The lesion was not attached to the underlying mandible or any musculatures. It was located in between overlying skin and what appears to be unremarkable underlying masseter muscle. The lesion was inseparable from the overlying skin on all images.

Incisional biopsy was carried out and the specimen sent for histopathological examination. Microscopic features of the decalcified sections showed sheets of eosinophilic cells, some with pyknotic nuclei while others with ghost-like appearance due to absence of nuclei. Basophilic mineralized material and ossification are present (Figure 1e). Patchy loose fibro-vascular connective tissue was noted adjacent to the lesional area. The

histopathological diagnosis reported for this incisional biopsy was that of a pilomatixoma.

Excisional biopsy under local anaesthesia was carried out with an incision made along the skin line to reduce the scar formation. Exploration was done using mosquito forceps to detach the lesion from the skin (Figure 1f and 1g). The bony mass was successfully removed in one piece without any complications (Figure 1h). Surgical site was cleaned with normal saline and the skin was sutured. The histopathology of the excisional biopsy specimen confirmed the previous diagnosis of pilomatixoma.

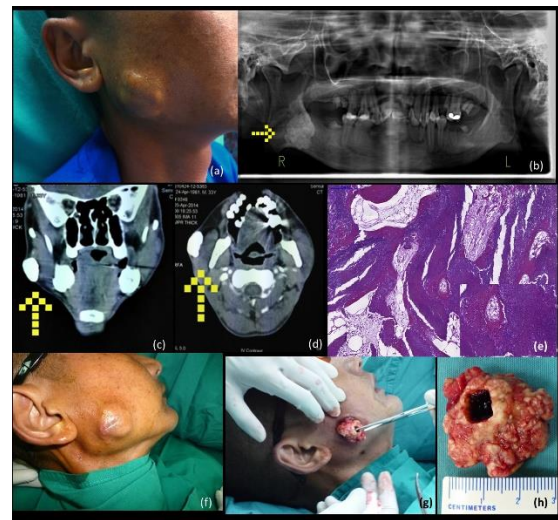


Figure 1: (a) Photograph show a swelling at the right cheek in the right parotid region anterior to the right side angle of mandible measuring 3.0 cm x 3.0 cm. (b) DPT show a well-defined radiopaque mass (yellow arrow) on the right side of the mandible, anterior to the angle of right side of mandible measuring 3.0 cm x 3.0 cm in size. (c, d) CT scan (coronal & axial view) show a non-infiltrating hyperdense lesion (yellow arrows) noted at the lateral part of the right mandible with well-defined margin. (e) Photomicrograph show basophilic mineralized material and ossification along with sheets of eosinophilic cells and ghost cells (insert) (H & E stain; 100 x magnification; Insert: H & E; 400x magnification). (f) Photograph show surgical site with incisional biopsy scar noted on the skin region over the swelling. (g) Incision was made along the skin line and the bony lesion seen. (h) Photograph show the macroscopic finding of a bony nodular lesion of 3.0 cm x 3.0 cm in size. The centre of bony lesion shows the incisional biopsy defect.

DISCUSSION

Although pilomatixoma can be found in any age groups of patients, it occurs most often in children

and young adults [12]. The greatest incidence of this tumour is found in patients between 8 and 13-year-old. Turh Han-Haktanir et al (2009) reported, pilomatrixoma has biphasic age distribution. It primarily affects children and adolescents, with greater than 60% of cases occurring before the third decade [13]. In this case report, the patient claimed to have had the bony swelling since childhood however, he presented to the clinic for removal of the swelling only in his early 4th decade.

Pilomatrixoma usually presents as an asymptomatic, superficial, solitary, firm swelling that is often accompanied by a reddish-blue discoloration of the underlying skin [14]. However, in this case, the patient presented with normal overlying skin colour suggestive of non-inflammatory skin condition. This lesion, which may be soft and cyst-like in its early course, is characteristically rock-hard when completely developed [13]. In this case, the patient had a painless, bony hard swelling in the right side of the mandible at the angle.

This tumour like the present case, has widely been reported as slow growing. The most common sites involved are the head and neck region (73%) and the upper limb (23%), as well as trunk and lower extremity [15]. In the head and neck region, the common areas affected are the cervical, temporal, eyelid and preauricular regions [13].

Multiple and recurrent lesions in the same patients coupled with reports of familial incidence have generated much interest in the genetics of this lesion. According to Kumaran et al. (2006), associations are reported between tumour and disorders such as myotonic dystrophy, Rubinstein-Taybi syndrome, Turner syndrome Gardner syndrome, xeroderma pigmentosum and basal cell syndrome [15]. The aetiology of this tumour is not completely understood but there are suggestions that an activating mutation in the Beta-catenin gene [16].

CTNNB1 is a gene that encodes beta-catenin. This gene has been reported to have undergone mutation in benign pilomatrixoma. This gene is a downstream effector in the WNT-signalling pathway. The beta-catenin protein was shown to be

expressed in the nucleus of the hair follicle cells using immunohistochemistry and the mutation occurs in exon 3, which was shown by DNA sequencing. However, CTNNB1 mutation has been reported in cases with multiple pilomatrixoma and pilomatrix carcinoma, implying that a common initial pathogenesis exists in both benign and malignant counterparts [17].

Malignant pilomatrixomas are locally aggressive tumours with a tendency to recur locally. Literature review by Mikhaeel and Spittle (2001), revealed that local control was achieved in up to 78% of the 55 cases reported. Of these, 21 patients (49%) went on to develop local recurrence [18]. Metastatic disease is rare. Metastases to the lung, bone and lymphatics have been described [19].

The diagnosis of pilomatrixoma can be made preoperatively based on clinical presentation, radiographic examination and histopathological findings. 'Tent sign' is the pathognomonic sign of pilomatrixoma and can be done by stretching of the skin overlying the mass with multiple facets and angles. Tetter-totter sign also suggestive of pilomatrixoma as pressing on one edge of lesion causes opposite site to protrude from the skin. Clinical presentation of pilomatrixoma may be misdiagnosed in the initial stage due to characteristic blue-red discoloration of the overlying skin which may mimic several benign lesions including sebaceous cyst, vascular malformations, hematoma and dermoid/epidermoid cyst.

Preoperative investigations with computed topography (CT) scan, magnetic radiofrequency imaging (MRI) and ultrasound are very useful as adjunct tools in diagnosing a pilomatrixoma. CT scan of pilomatrixoma revealed a non-infiltrating mass containing calcifications located within subcutaneous tissue [20]. MRI findings of pilomatrixomas are that of homogenous intermediate T1-weighted signal intensity, low to intermediate T2-weighted signal intensity without enhancement. Ultrasound is non-invasive, fast and inexpensive, and can be performed even in children or babies without sedation or general anaesthesia [20]. In this case, DPT and CT scan was carried out. However, the radiographic imaging findings have

little diagnostic value as it were unable to differentiate pilomatrixoma from other subcutaneous tumour.

Fine needle aspiration biopsy with or without guided ultrasound scan revealed clustered or isolated basaloid cells with variably sized nuclei and prominent nucleoli along with multinucleated giant cells and either ghost cells or acellular masses suggestive of ghost cells nests [14] can aid in diagnosing pilomatrixoma [20]. However, FNAC may be misleading if ghost cells are not aspirated.

The characteristic histological appearance of pilomatrixoma is that of nests of small basaloid cells that undergo keratinization [21]. Ghost cells are the matured basaloid cells that are predominantly eosinophilic and tend to lie in the centre of cells islands. Basaloid cells evoke a foreign body response with giant cells formation and dystrophic calcification [22]. In some tumours, eosinophilic structures representing immature hairs are seen [7]. Benign pilomatrixoma are thought to be derived from actively proliferating tissues, where mitotic figures may be identified.

The diagnosis of pilomatrixoma depends on histological examination in order to exclude fibroma calcinosis cutis, ossifying osteoma, epidermal inclusion cyst and dermoid cyst [23]. The other differential diagnoses should be considered and need to be ruled out are intraparotid/periparotid tumours, brachial cyst, hemangioma, inflammatory lesion [21], as well as giant cell tumour, foreign body reaction, degenerating fibroxanthoma and metastatic bone formation [14].

REFERENCES

1. Forbis R, Helwig EB. Pilomatrixoma (calcifying epithelioma). Arch Dermatol. 1961;83:606-618.
2. Malherbe A, Chenantais J. Note sur l' epithelioma calcifie des glandes sebacees. Prog Med 1880;8:826-828.
3. Forbis R Jr, Helwig EB. Pilomatrixoma (calcifying epithelioma). Arch Dermatol. 1961;83:606-618.
4. Kaddu S, Soyer HP, Hödl S, Kerl H. Morphological stages of pilomatrixoma. Am J Dermatopathol. 1996;18(4):333-338.
5. Knight PJ, Reiner CB. Superficial lumps in children: What, when, and why? Pediatrics. 1983;72:147-153.
6. Moehlenbeck FW. Pilomatrixoma (calcifying epithelioma): a statistical study. Arch Dermatol. 1973;108:532-534.
7. Rink B. Pilomatrixoma in the oro-facial region. Int. J. Oral Maxillofacial Surgery. 1991;20:196-198.

Treatment for pilomatrixoma is complete surgical excision as no spontaneous regression has been reported [24]. Yoshimora et al. (1997) reported and recommended that pilomatrixoma should be excised completely, together with adherent skin, though in some cases incision and curettage may be adequate [25]. Further recommendation to remove the tumour with safety margins in order to minimize the risk of recurrence of the malignant variants is also suggested. The risk of facial numbness or palsy would be relatively low as the tumour presents just under the skin and there is lack of continuity with the parotid gland and the masseter muscle. The follow-up times were variable and most are short time review session.

CONCLUSIONS

In conclusion, pilomatrixoma is a benign tumour of hair follicle cells which can be often misdiagnosed. Therefore, clinicians should be aware of this entity and to consider pilomatrixoma as a differential diagnosis in case of superficial swelling of the head and neck region. The imaging findings of a non-infiltrating bony lesion containing calcifications located within subcutaneous tissues of head and neck should raise the possibility of a pilomatrixoma.

ACKNOWLEDGEMENT

The authors would like to acknowledge the authors and publishers of all those articles and journals that has been cited in this manuscript.

DECLARATION OF INTEREST

The authors report no conflicts of interest. The authors alone are responsible with the content of this article.

8. Harper PS. Calcifying epithelioma of Malherbe. Association with myotonic muscular dystrophy. *Archives of Dermatology*. 1972;106(1):41–44.
9. Pujol RM, Casanora JM, Egido R, Pujol I. Multiple familial pilomatrixoma: a cutaneous marker for Gardner syndrome? *Pediatr Dermatol*. 1994;12:331-335.
10. Noguchi H, Kayashima K, Nishiyama S, and Ono T. Two cases of pilomatrixoma in Turner’s syndrome. *Dermatology*. 1999;199(4):338–340.
11. Cambiaghi S, Ermacora L, Brusasco A, Canzi L, Caputo R. Multiple pilomatricomas in Rubinstein-Taybi syndrome: a case report. *Pediatr Dermatol*. 1994;11:21-25.
12. Chuang C-C, Lin H-C. Pilomatrixoma of the Head and Neck. *J Chin Med Assoc*. 2004;67:633-636.
13. Turhan-Haktanir N, Demir Y, Sahin O, Bukulmez A, Tuzuner M. Pilomatricoma : A review of six pediatric cases with nine lesions. *The Turkish Journal of Pediatrics*. 2009;51:44-48.
14. Som PM, Shugar JMA and Silvers AR. CT of Pilomatrixoma in the Cheek. *AJNR Am J Neuroradiol*. 1998;19:1219-1220.
15. Kumaran N, Azmy A, Carachi R, Raine PAM, Macfarlane JH, Howatson AG. Pilomatrixoma – accuracy of clinical diagnosis. *Journal of Pediatric Surgery*. 2006;05:005:1755-1758.
16. Xia J, Urabe K, Moroi Y, Koga T, Duan H, Li Y, Furue M. Beta-catenin mutation and its nuclear localization are confirmed to be frequent causes of Wnt signalling pathway in pilomatrixomas. *J Dermatol Sci*. 2006;41:67-75.
17. Lazar AJ, Calonje E, Grayson W, Dei Tos AP, Mihm Jr MC, Redston M, McKee PH. Pilomatrix carcinomas contain mutations in CTNGB1, the gene encoding beta-catenin. *J Cutan Pathol*. 2005;32(2):148-157.
18. Mikhaeel NG and Spittle MF. Malignant Pilomatrixoma with multiple local recurrences and distant metastases: A case report and review of literature. *Clinical Oncology*. 2001;13:336-389.
19. Sassmannshausen J and Chaffins M. Pilomatrixoma carcinoma: A report of a case arising from a previously excised pilomatrixoma and a review of the literature. *J Am Acad Dermatol*. 2001;44:358-361.
20. Kawakami M, Yoshimura K, Ito K, Tanaka H, Higashikawa M, Hyo S. Two Cases of Pilomatrixoma in the cheek. *Bulletin of the Osaka Medical College* 2004;50(1,2):13-17.
21. Kashima K, Igawa I, Takamori K, Yoshioka I, Sakoda S. A case of pilomatrixoma in the cheek in a 7 year old girl. *Oral Science International*. 2012;9:26-28.
22. Neto JAM, Raposo RM, Segalla DK, Leonhardt FD. Pilomatrixoma in head & neck. *Braz J Otorhinolaryngol*. 2009;75(4):618.
23. Williams MD, Pearson MH, Thomas FD. Pilomatrixoma : a rare condition in the differential diagnosis of a parotid swelling. *British Journal of Oral Maxillofacial Surgery*. 1991;29:201-203.
24. Saussez S, Mahillon V, Blaivie C, Haller A, Chantrain G, Thill MP. Aggressive pilomatrixoma of the infra-auricular: A case report. *Arch Nasus Larynx*. 2005;32:407-410.
25. Yoshimura JY, Obara S, Mikami T, Matsuda S. Calcifying epithelioma (pilomatrixoma) of the head and neck: analysis of 37 cases. *British Journal of Oral Maxillofacial Surgery*. 1997;35:429-432.

Editorial History

Date of Submission: 04 December 2019

Review and Revision: 19 December 2019 to 02 April 2020

Accepted: 13 July 2020

Published: 19 August 2020

License Information: This work is licensed under a Creative Commons Attribution