

# ALVEOLAR BONE GRAFTING WITHOUT CLOSURE OF ORO-NASAL FISTULA IN CLEFT LIP AND PALATE PATIENT

Z.A. Abdul Rahman. *Alveolar Bone Grafting without Closure of oro-nasal fistula in cleft lip and palate patient. Annal Dent Univ Malaya 2004; 11: 37-40.*

## ABSTRACT

The standard procedure for alveolar cleft closure in cleft lip and palate patients is by alveolar bone grafting (ABG) where the residual opening of oronasal fistula in the palate is also closed simultaneously. Occasionally there is a situation of soft tissue inadequacy and attempt to close the fistula at the same procedure as ABG may compromise the result of the bone graft itself. An unforeseen leakage at the closure may cause graft infection leading to failure. This article reports on a technique where alveolar bone grafting was done without closure of residual palatal fistula to provide adequate soft tissue coverage for the grafted bone. This may reduce the risk of leakage at the oral mucosal coverage of the graft. The residual palatal fistula will be closed at later stage by muco-palatal flap or tongue flap. We reported on a case of a failed ABG which was reconstructed using this technique. Various other techniques to ensure success of ABG were also discussed. Conclusion: The alveolar bone grafting without closure of oro-nasal fistula reduced the risk of failure of ABG in a wide alveolar cleft.

Key words: alveolar bone grafting, oro-nasal fistula, cleft lip and palate.

## INTRODUCTION

Cleft alveolus usually occurred as part of cleft lip and palate (CLP) deformity. Over the years management of cleft alveolus had been innovated to provide better results. There is a vast variation on type and source of graft used, timing of the surgery and type of soft tissue flap covering the graft.

Primary ABG is usually done from first day of life to 2.5 years old. Early secondary ABG were done at between ages of 2 to 5 years old. Secondary bone grafting is carried out between the ages of 6 to 13 years old. Late ABG will be done after 13 years of age. Sometimes ABG was done together with Le fort 1 osteotomy procedure (1). Secondary alveolar bone grafting is usually preferred to primary grafting as the later showed to cause growth disturbances (2, 3).

Gingival mucoperiosteal flap is the most recommended method of bone graft coverage. The attached gingival covering the bone will provide an excellent cuff around the tooth that erupt through it.

Z.A. Abdul Rahman

*Associate Professor / Consultant  
Oral and Maxillofacial Surgeon  
Department of Oral and Maxillofacial Surgery  
Dental Faculty  
University of Malaya  
Kuala Lumpur.*

Secondary alveolar bone grafting technique was introduced by Boyne and Sand (4) in 1972 and later popularized by Abyholm and Semb (5) in 1981. This is a technique where cancellous bone were harvested from iliac crest and grafted at the cleft alveolus of CLP patient. This technique had various modification world wide.

Usually the nasal lining is created by making incision around the margin of cleft alveolus (Fig.1). Mucoperiosteum flap was raised and this was later push upwards to allow space for bone graft (6). This flap was sutured to ensure complete nasal seal. The bone graft is packed in the cleft alveolus space then covered with buccal advancement flap at the bucco-gingival side and palatal rotation flap at the palatal area. Occasionally there is lack of soft tissue coverage of the graft which increased risk of failure. These situations include large cleft alveolus or large residual palatal fistula. The scarred palate from previous surgery worsen the situation. It is important to have a water tight closure over the graft to prevent tracking in of infection from the oral or nasal cavity. In the attempt for simultaneous closure of palatal fistula during alveolar bone graft sometime there is risk of soft tissue deficiency which may cause tension along the wound. This may lead to leakage and wound dehiscence which were noted in many failed ABG. In this situation it is important to concentrate on ensuring the success of the bone graft and close the oronasal fistula later.

## Case reports

A 10 year old Malay girl was referred to our Department for management of failed ABG. The graft disappeared about 1 week after the surgery. On examination, unilateral cleft alveolus and residual fistula persist on the right side. Radiographs showed a small strut of residual grafted bone bridging the cleft alveolus (Figure 1a). After discussion with the parents, the patient was then scheduled for second ABG without closure of oro-nasal fistula under general anaesthesia.

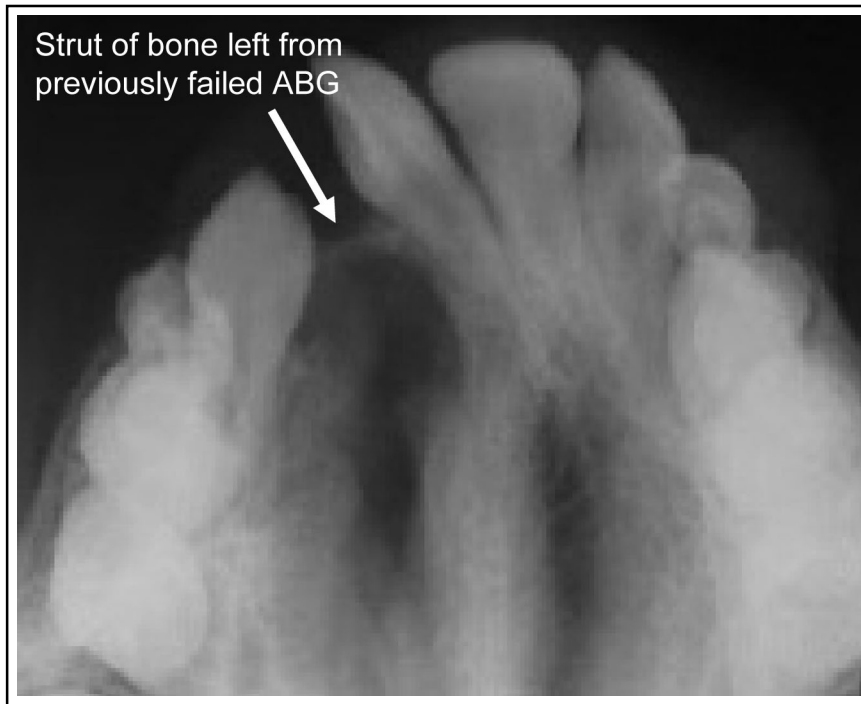


Figure 1a

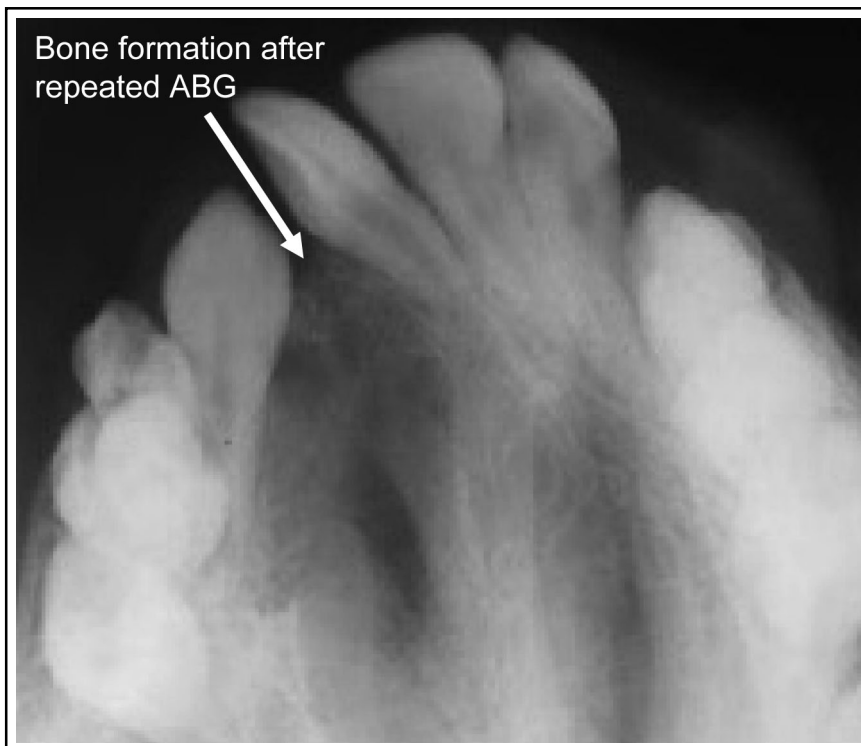


Figure 1b

The patient had nasal endotracheal intubation in the non-cleft side. Following infiltration with local anaesthetic, an incision was made at the margin of alveolar cleft on the buccal side. The incision stop short of the crest of alveolus (Figure 2a). The gingival mucoperiosteal flap was raised and reflected posteriorly (Figure 2b). The attachment at the apex of the cleft alveolus was also dissected following the continuation of cleft alveolus to floor of the nose. The flap that was reflected posteriorly was then sutured to form a bed to lay bone graft (Figure 2b).

Gingival crevice incision was then made along the buccal gingival on the left and right side of the cleft and another bucco- gingival mucoperiosteal flap was raised (Figure 2b). Relieving incision was made on first molar of the cleft side to allow the flap to be advance to cover the bone graft. The periosteum of the flap was also incised to allow further relief of the flap. The cancellous bone chips harvested from iliac crest were packed into the bone defect (Figure 2c). The buccal flap was then advanced and sutured together over the bone graft (Figure 2d). No evidence of infection, bone loss and leakage found during post-operative follow up. Occlusal radiograph taken 3 months later showed good bone formation at the cleft alveolus site (Figure 1b).

## DISCUSSION

Failures of alveolar bone grafting are quite common especially in cases of wide alveolar clefts or large residual palatal fistulas. Common complications of alveolar bone graft include donor site morbidity, graft exposure and graft loss (3). In view of donor site morbidity it is important to ascertain the success of the first procedure. This technique will allow ample soft tissue closure and prevent graft exposure and loss thus have better chances of success.

In the earlier phase the bone graft is totally dependent on the nourishment by diffusion from the vessels of surrounding tissue. Therefore it is important to have good tissue coverage around the bone to ensure sufficient nourishment of the graft

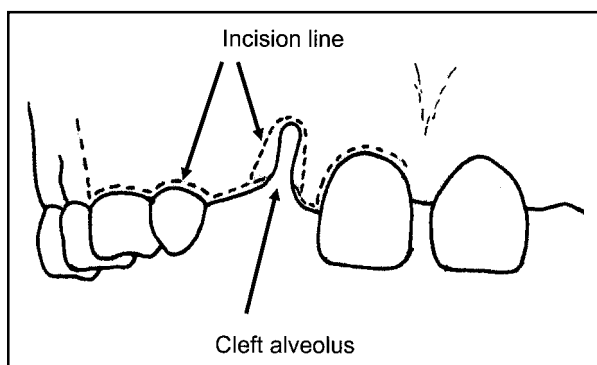


Figure 2a

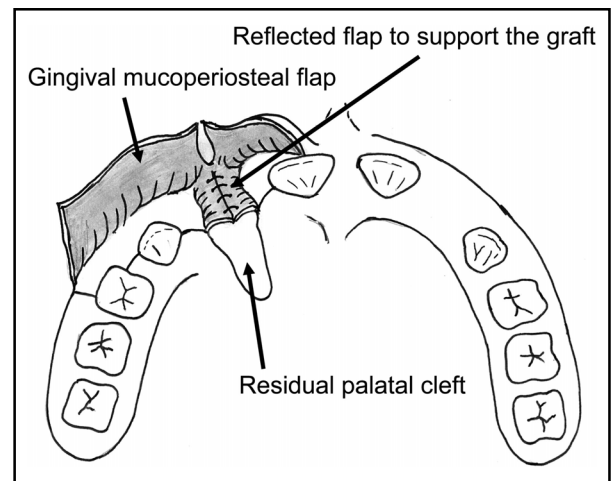


Figure 2b

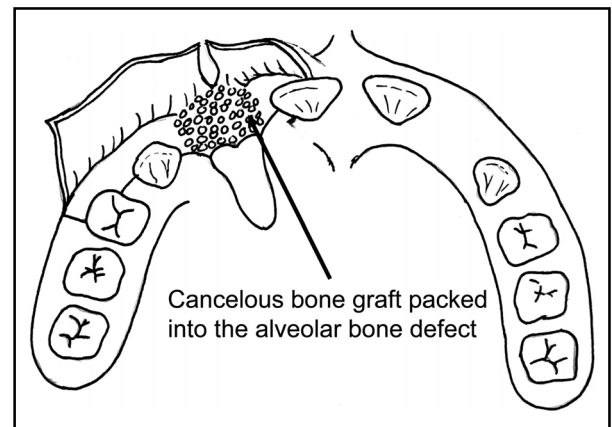


Figure 2c

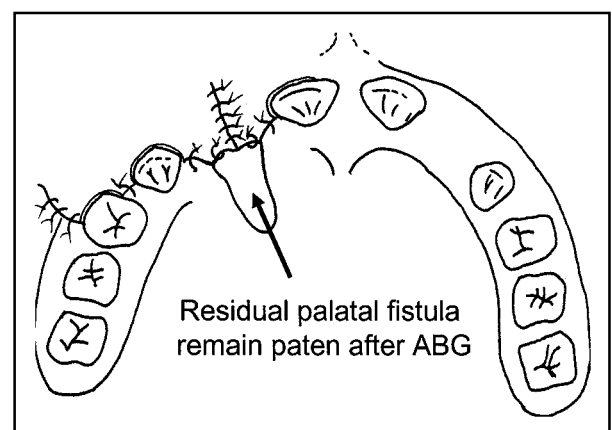


Figure 2d

before new blood vessels are established within the graft.

Various other techniques have been introduced to prevent failure of ABG in wide alveolar clefts. Binger et al (7) had suggested using distraction osteogenesis to bring the lateral segment closer to the mesial segment in wide alveolar cleft. This will ensure

sufficient soft tissue coverage. However this is time consuming as the distractor must be worn for 10 weeks and another procedure is required to place the distractor.

Kondoh et al (8) had recommended the use of cotton gauze impregnated with cyanoacrylate to prevent wound dehiscence, mechanical injuries and food adhesions over alveolopalatal wound. The technique was applied to 74 patients and no infections were found, however four patients had tiny fistulas. We can infer from here that sometime fistulas recurrence over the alveolopalatal are unavoidable. This fact will makes technique more appreciable as it does not deal with alveolopalatal areas during the grafting.

Besides providing good soft tissue coverage, the surgical procedure involved in this technique is also less demanding. This is because the tedious procedure of suturing the nasal lining across the palatal defect is not required during the bone grafting.

Kamakura et al (9) has reported a successful 2 stage secondary alveolar bone grafting in bilateral cleft alveolus. The ABG was done one side at a time. It is quite an acceptable way of preventing failure however the patient undergoes the surgery twice.

## CONCLUSION

The technique of ABG without closure of oro-nasal fistula has good assurance of success as it allows the grafted bone to have a tension free and water tight soft tissue wrap around it. This technique is especially recommended for patient with wide alveolar cleft or large palatal fistulas.

## REFERENCES

1. Stassen LFA. Alveolar bone grafting- How do I do it. In: Ward-Booth, Schendel & Hauseman ed. *Maxillofacial Surgery*. Churchill Livingstone, 1999: 1047–55.
2. Hynes PJ, Earley MJ. Assessment of secondary alveolar bone grafting using a modification of Bergland grading system. *Br J Plast Surg*. 2003 Oct; 56(7): 630–6.
3. Bajaj AK, Wongworawat AA, Punjabi A. Management of alveolar clefts. *J Craniofac Surg*. 2003 Nov; 14(6): 840–6.
4. Boyne PJ, Sands NR. Secondary bone grafting of residual alveolar and palatal cleft. *J Oral Surg* 1972; 30: 87.
5. Abyholm FE, Bergland O, Semb G. Secondary bone grafting of alveolar clefts. A surgical / orthodontic treatment enabling a non-prosthetic rehabilitation in cleft lip and palate patients. *Scand J Plast and Recons Surg* 1981. 15: 127–40.
6. Hammond M. Alveolar bone grafting for cleft lip and palate patients. *Dent Update* March 1993: 62–4.
7. Binger T, Katsaros C, Rucker M, Apitzer WJ. Segment distraction to reduce a wide alveolar cleft before alveolar bone grafting. *Cleft Palate Craniofac J*. 2003 Nov; 40(6): 561–5.
8. Kondoh S, Matsuo K, Yuzuriha S, Kikuchi N, Ban R. Dressing for alveolopalatal wounds after alveolar bone grafting. *Ann Plast surg*. 2003 Sep; 61(9): 1078–81.
9. Kamakura S, Yamaguchi T, Kochi S, Sato A, Montegi K. Preliminary report of two stage secondary alveolar bone grafting for patients with bilateral cleft lip and palate. *Cleft Palate Craniofac J*. 2003 Sep; 40(5): 449–52.